

Abdominal Wall Hernias

Definition

- Protrusion of a viscus through an opening in the wall of the cavity in which it is contained
- The size of a hernia is determined by the dimension of the neck and the volume of the distended sac
- Reducible (incarcerated) when the protruded viscus can be returned to the abdomen
- Strangulated when the vasculature is compromised, usu. At the neck.

Sites of herniation

- Where aponeurosis and fascia are devoid of support of striated muscle
- Most common sites:
 - Groin
 - Umbilicus
 - Linea Alba
 - Semilunar line of Spiegel
 - Diaphragm
 - Surgical Incision

Sites of herniation

- Other rare sites:
 - Perineum
 - Superior triangle of Grunfelt
 - Inferior lumbar line of Petit
 - Obturator
 - Sciatic foramen of the pelvis

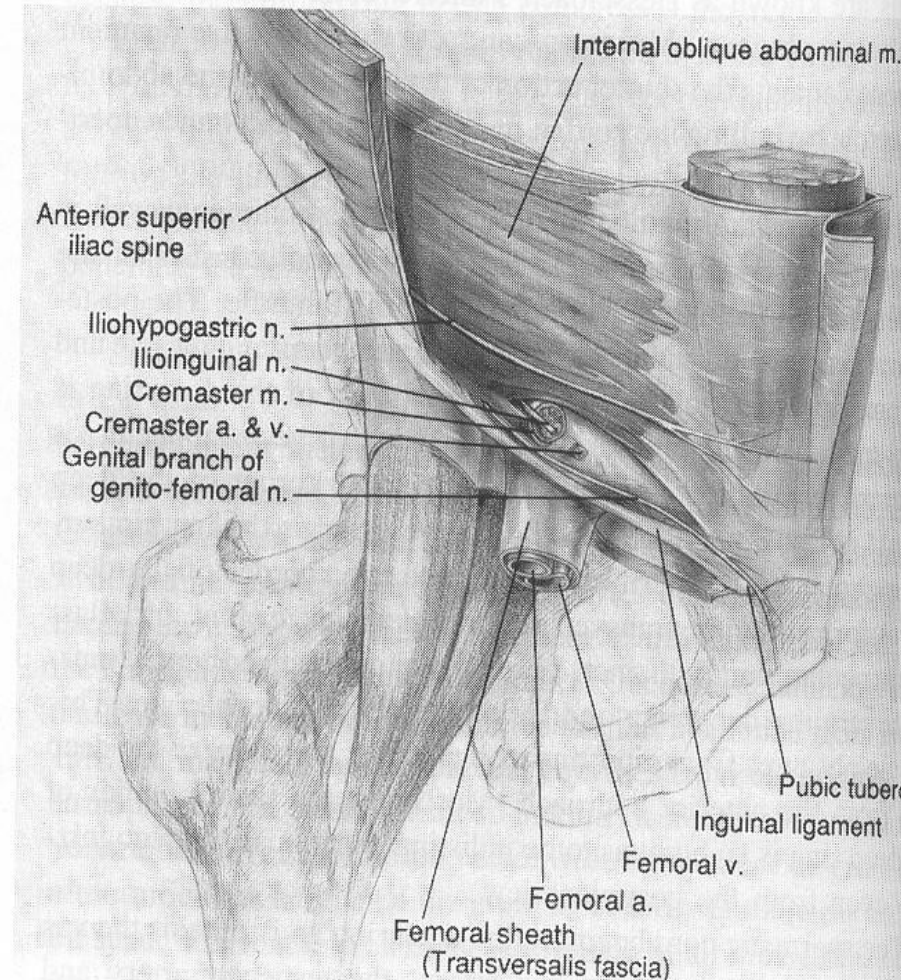
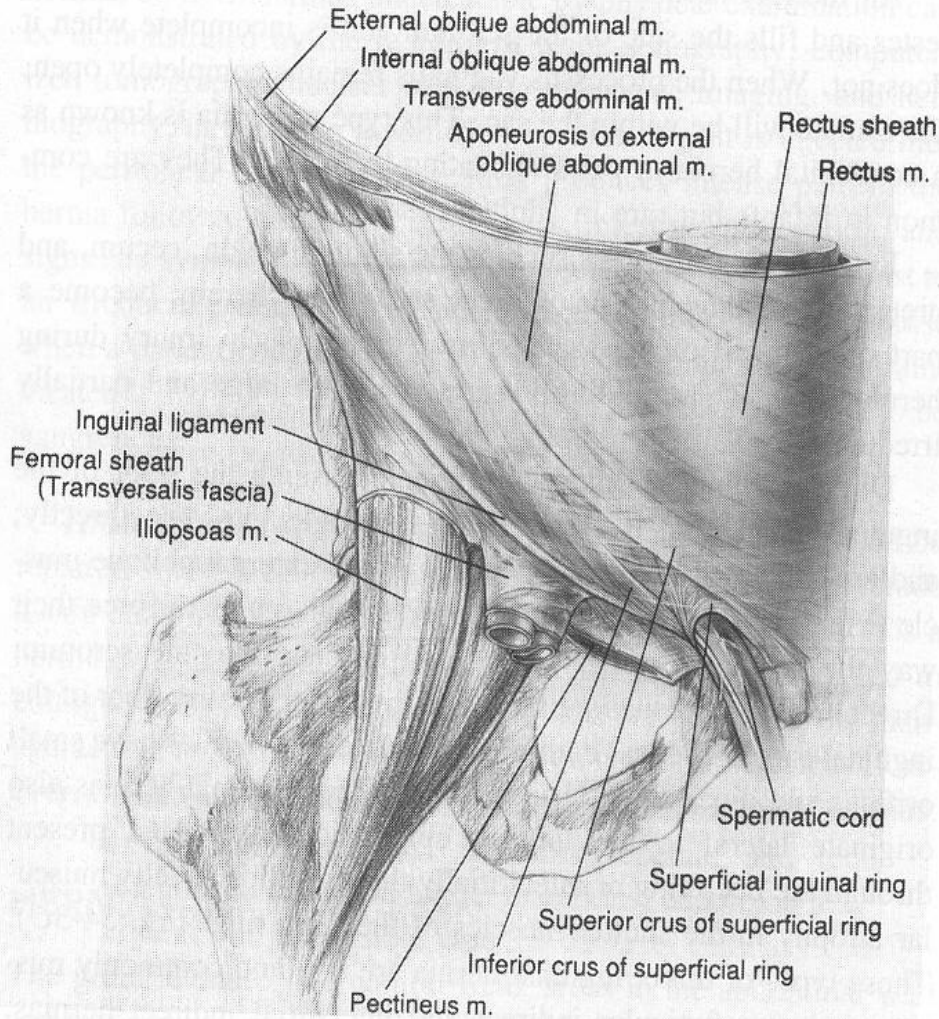
Indication for surgery

- All hernia should be repaired unless local or systemic conditions preclude a safe outcome
- Exception: a hernia with a wide neck and a shallow sac that is anticipated to enlarge slowly
- Trusses and surgical Belts are helpful in small hernias when operation is contraindicated. (NOT in Femoral H.)

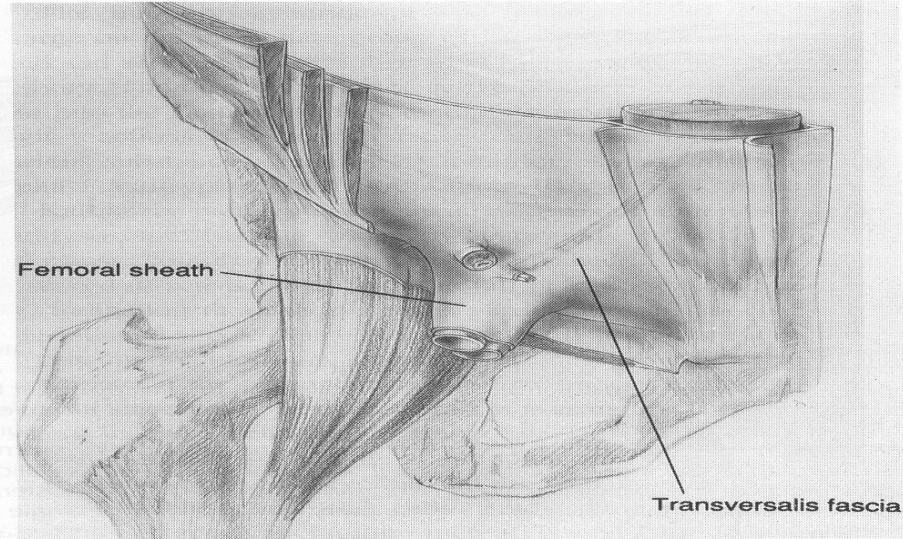
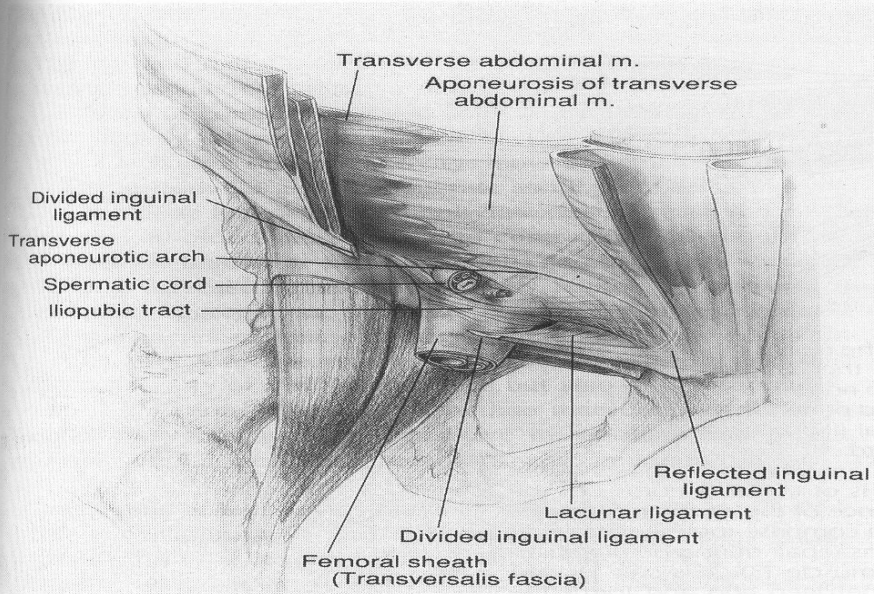
Hernias of the Groin

- Inguinal Most common
- Men= 25women Ind=2 Direct in men
- Incidence is 3% in men
- FH & IH are twice more on the right
- Femoral hernia is a hernia of the Groin
 - Uncommon in men
 - 10% of men affected will have IH later
 - 50% of Women will have IH later
 - Almost always present as an irreducible walnut size mass at the medial base of the Scarpa's femoral triangle.

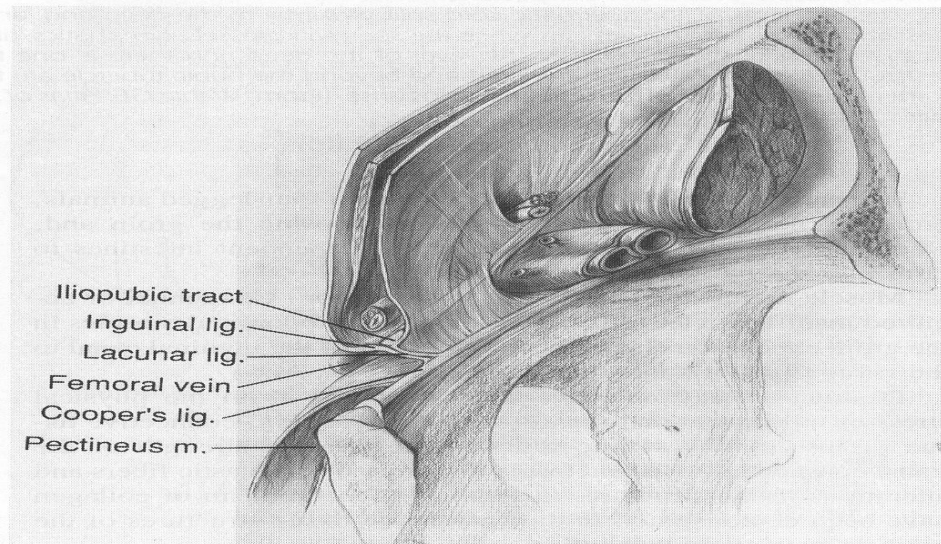
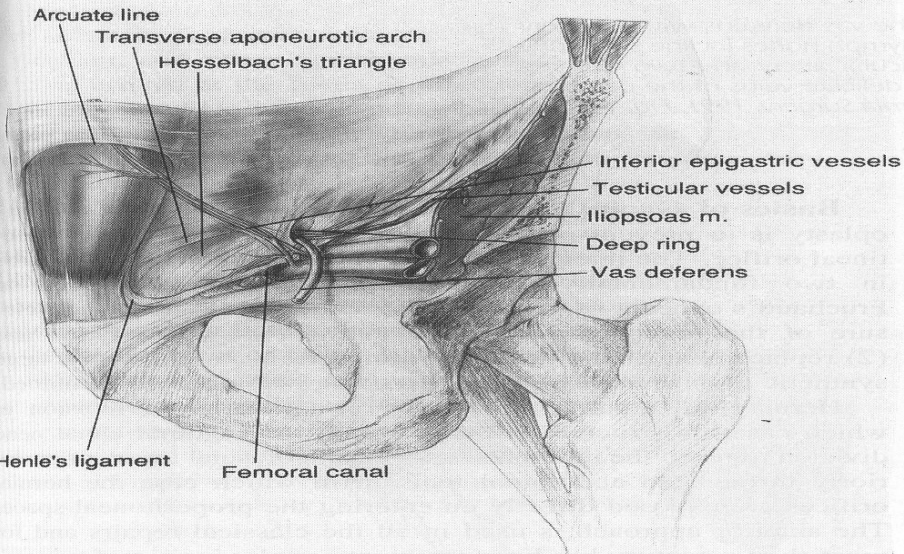
Anatomy of the Groin



Anatomy of the Groin



D



F

Hernia's Locations

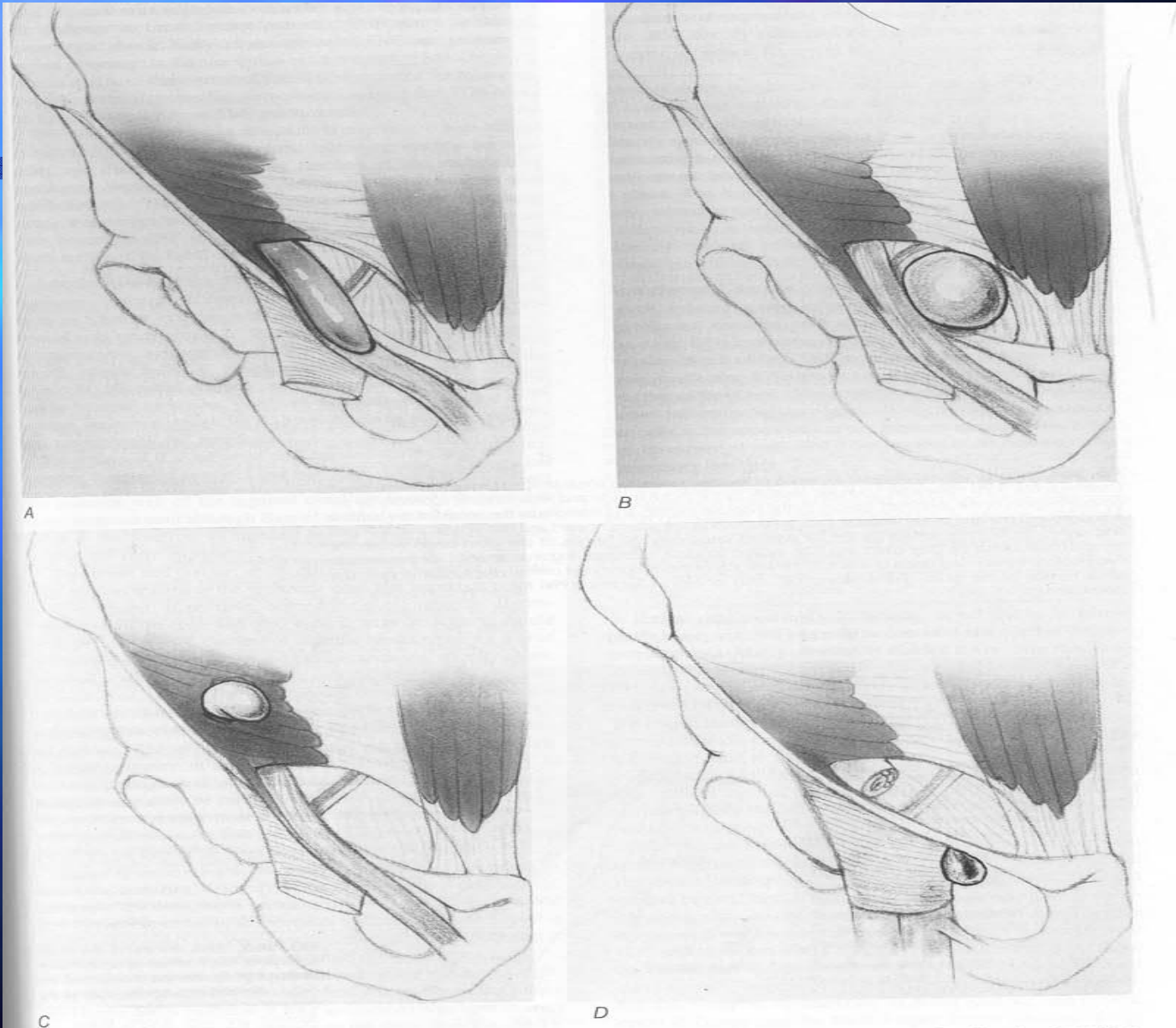
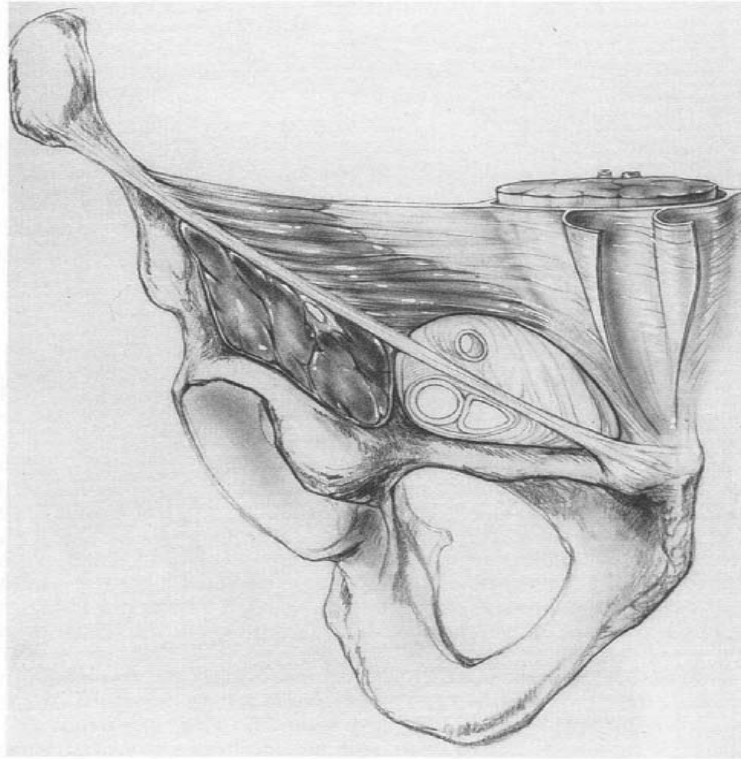


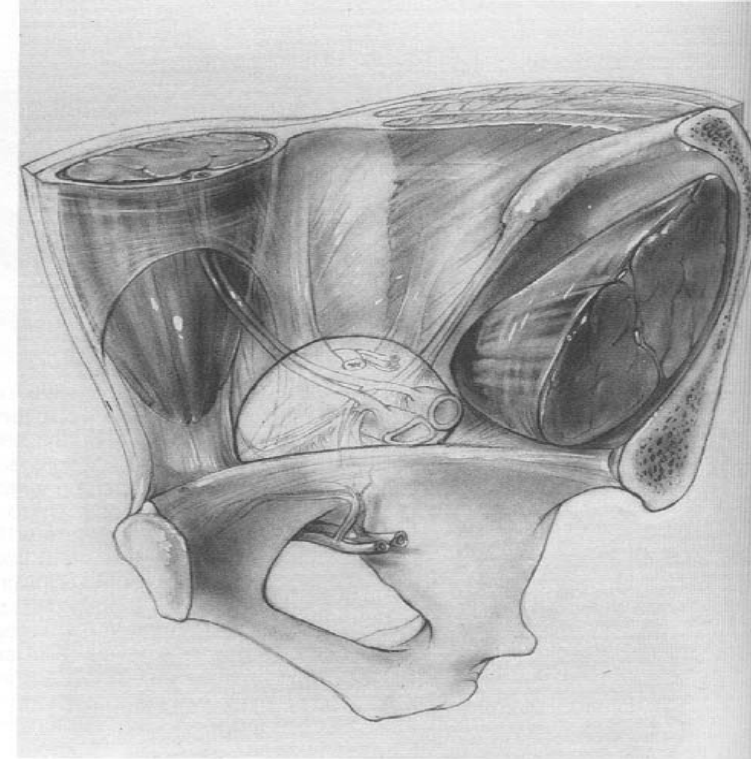
FIG. 34-3. The anatomy of hernia sacs in the groin: *A*, an indirect hernia sac; *B*, a direct hernia sac; *C*, an interstitial hernia; *D*, femoral hernia.

Frunchaud's Myopectinal Orifice

■ The fundamental cause of all groin hernias is the failure of the transversalis fascia to retain the peritoneum



A

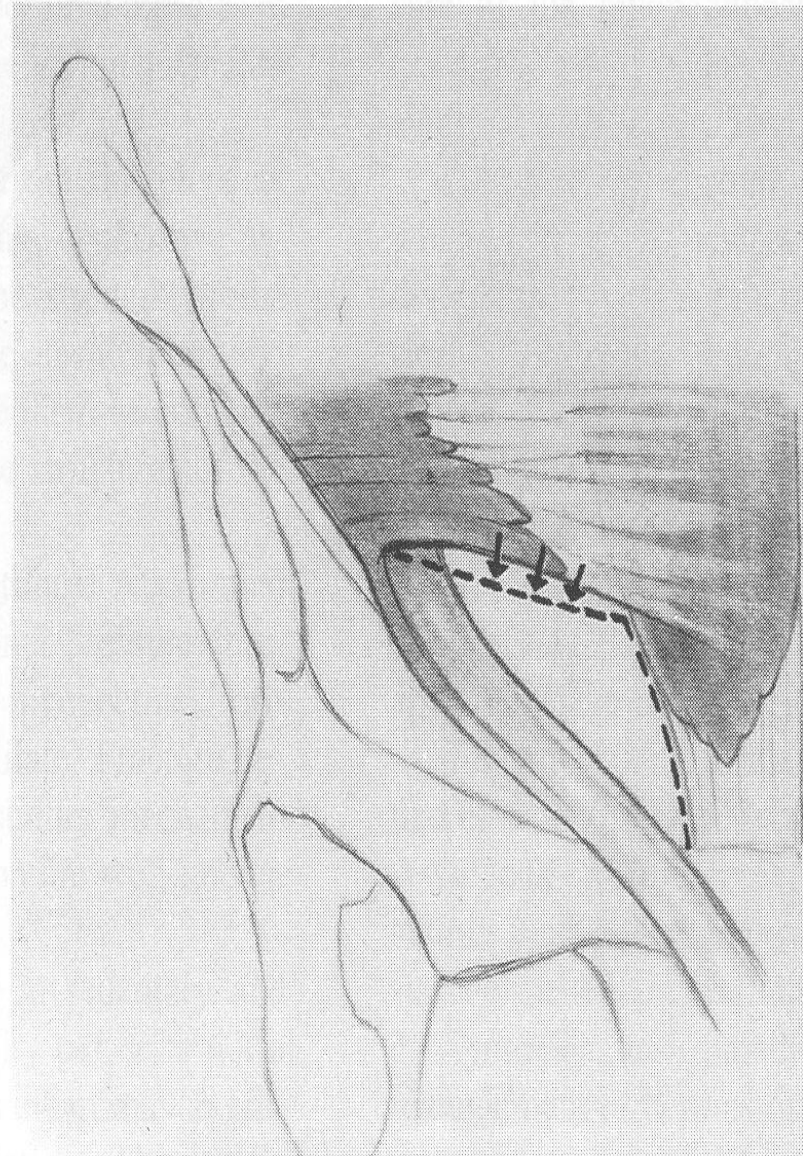
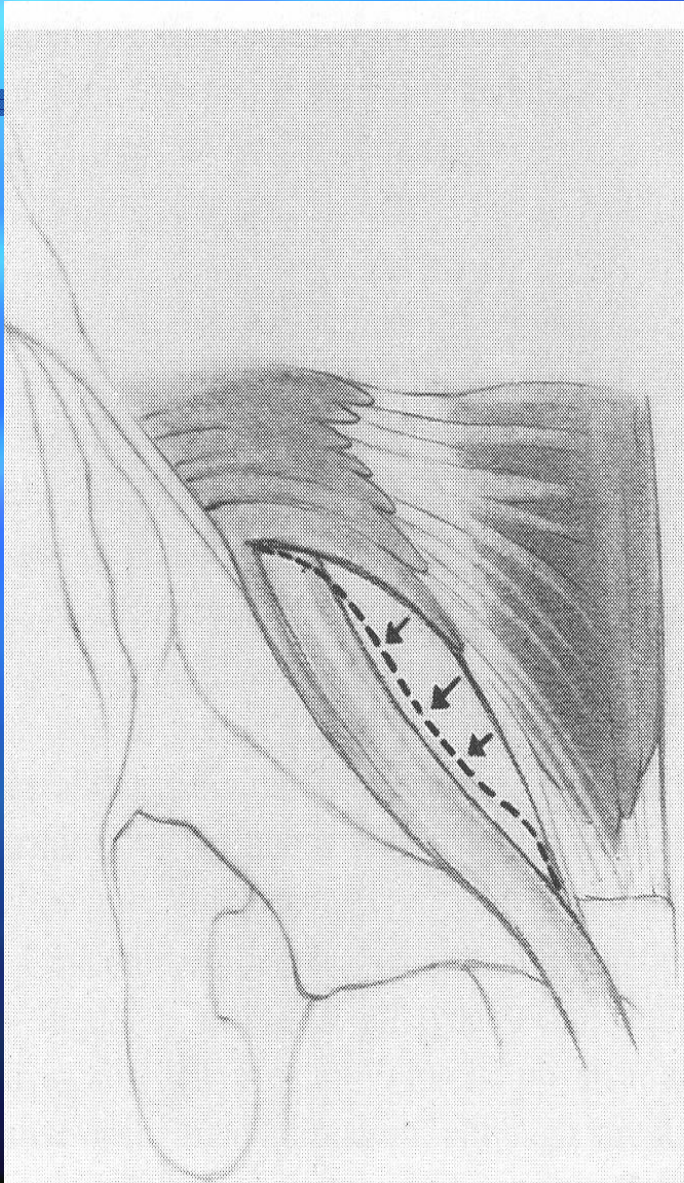


B

FIG. 34-4. Anterior (A) and posterior (B) views of Frunchaud's myopectinal orifice. The myopectinal orifice is the muscular bony framework bounded medially by the rectus muscle and rectus sheath, superiorly by the oblique muscles of the abdomen, laterally by the iliopsoas muscle, and inferiorly by the pecten of the pubis. It is bridged and bisected by the iliopubic tract, transversed by the spermatic cord and iliac vessels, and spanned and sealed on its inner surface by the transversalis fascia only. All hernias of the groin begin within the myopectinal orifice be they direct inguinal, indirect inguinal, interstitial inguinal, femoral, or prevascular. Failure of the transversalis fascia to maintain the integrity of the myopectinal orifice is the fundamental cause of all hernias of the groin. (From: *Wantz GE: Atlas of Hernia Surgery, 1991, Fig. 1-2a, b, pp 4-5, with permission.*)

Other Factor

- Insufficiencies of the internal oblique expose the deep ring to the intra-abdominal pressure



Hernioplasty: Basics:

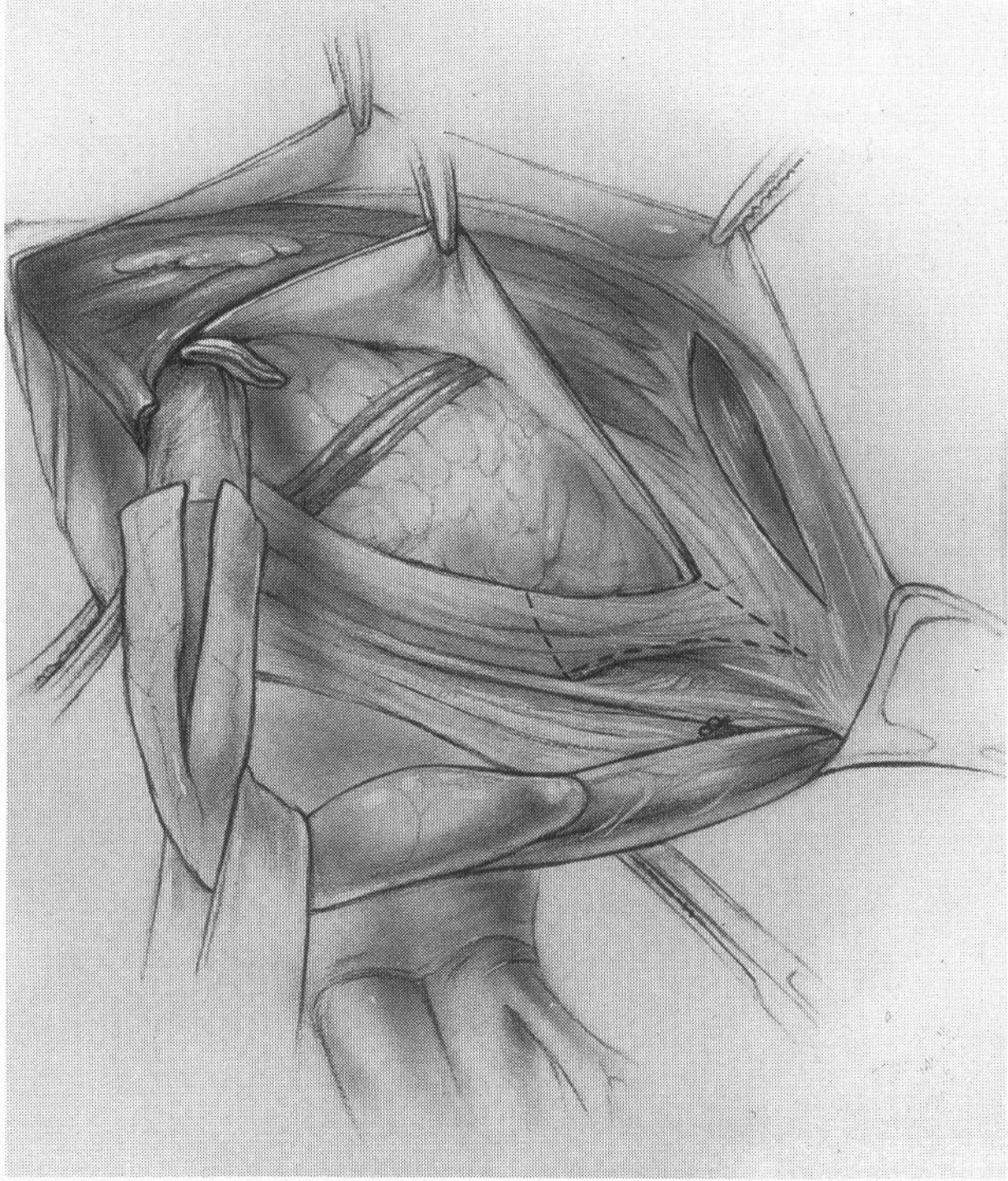
- Two fundamental Concepts:
 - Aponeurotic closure of the myopectinal orifice
 - Replacement of the defective transversalis fascia with a prosthesis
 - Or the two at the same time
- Tension is the principal cause of failure
- Two types:
 - Anterior or classical repair
 - Posterior or pro-peritoneal

Anterior Classical Groin Hernioplasty

- Only three approaches are still used:
 - Marcy simple repair
 - Bassini Repair (modified to Shouldice)
 - McVay-Lotheissen Cooper ligament repair
- Three parts:
 - Dissection of the Inguinal canal
 - Repair of the myopectinal orifice
 - Closure of the inguinal canal

A- Dissection of the IC consist of

- Opening of the IC
- Preservation of the ilioinguinal nerve
- Division of the cremaster muscle (often omitted by surgeons!)
- Exposure of the deep ring
- Mobilization of the spermatic cord
- Division + excision of the weak area in post wall of the inguinal canal (often omitted by surgeons!)
- Elimination of the peritoneal sac
- Removal of the cord lipoma
- DISSECTION IS AS IMP AS REPAIR



B- Repair of the myopectinal orifice

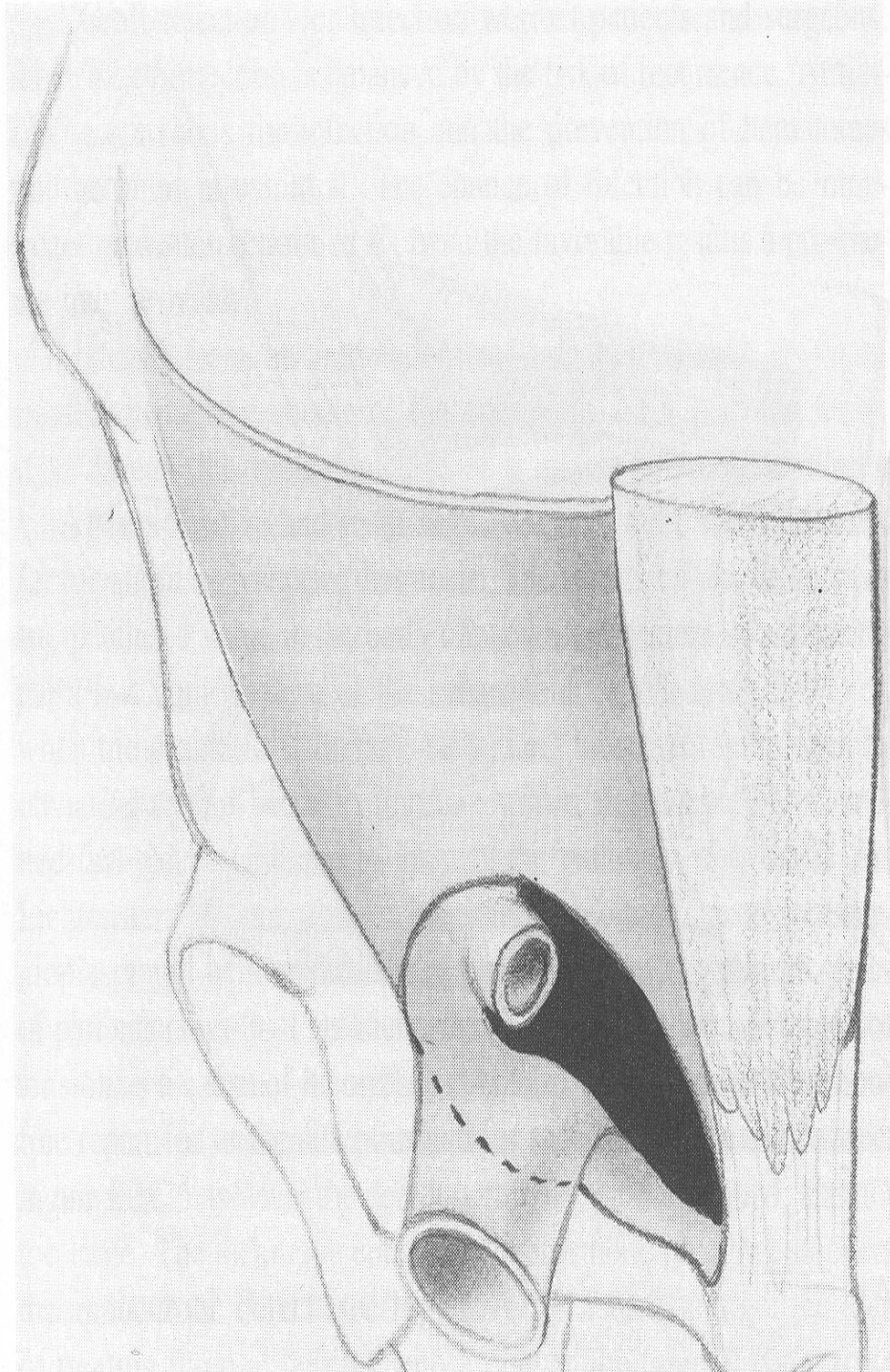
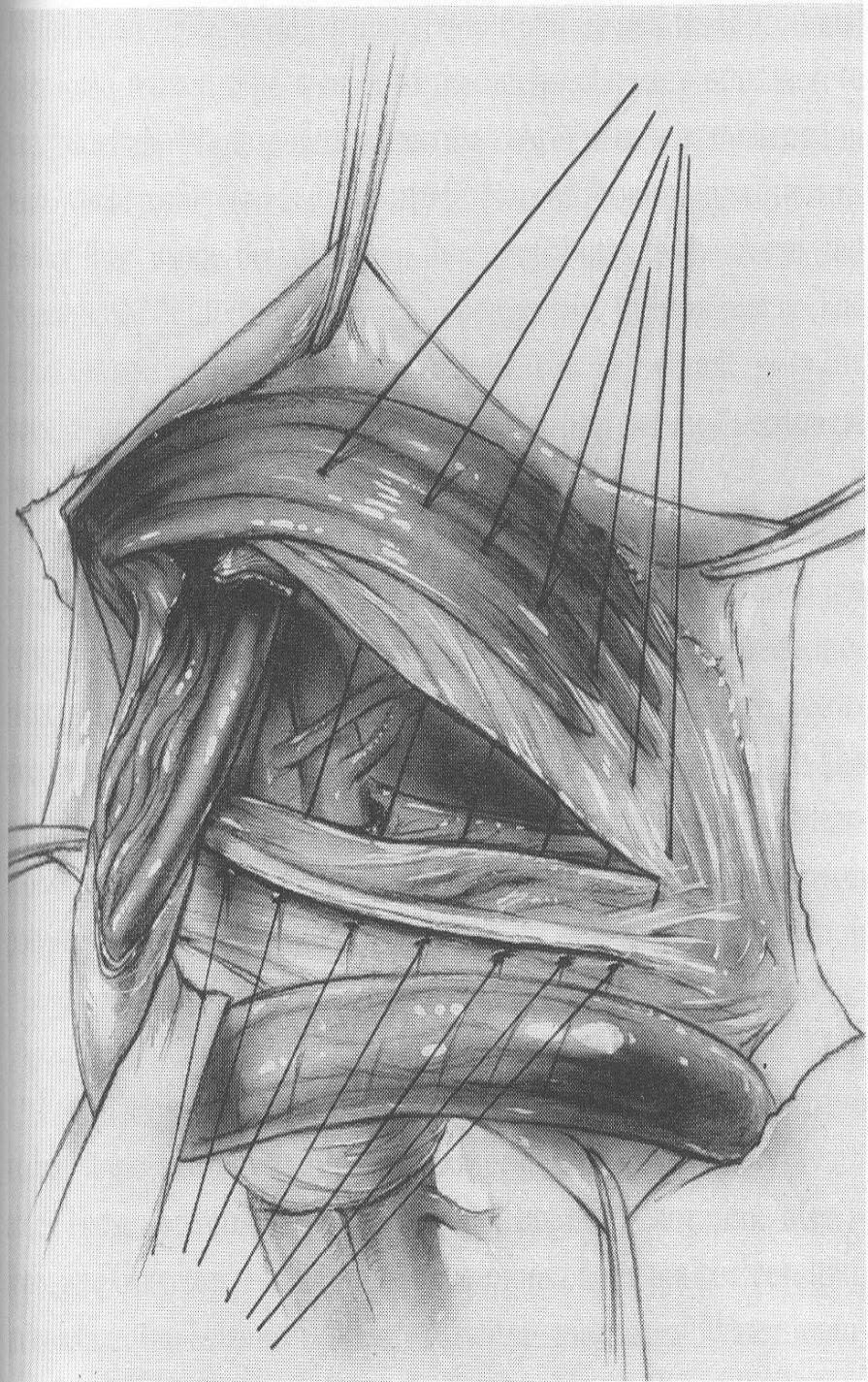
- Contrary to the belief of some surgeons, the anatomy of the deep ring is such that strangulation of the spermatic cord by reconstruction of the posterior wall of the inguinal canal is virtually impossible.
- Indeed, insufficient repair of the deep ring is the principal cause of indirect recurrence

Marcy Repair

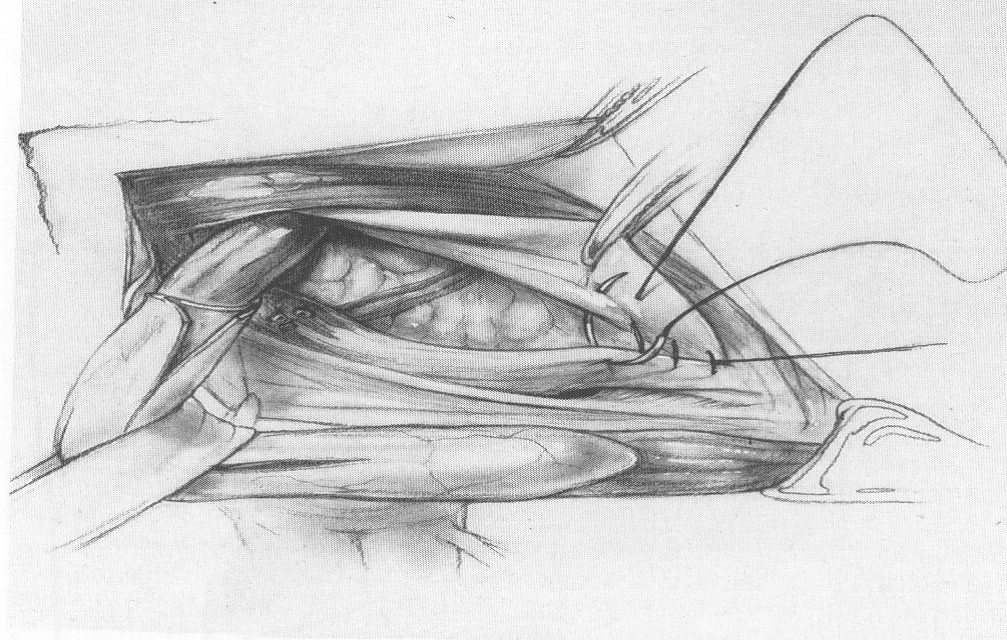
- Called simple ring closure
- It consists of tightening an enlarged deep ring only
- Is indicated in men and women who have indirect hernia with only minimal damage to the deep ring
- Is the hernioplasty of choice for women with indirect inguinal hernia
- After dividing the round ligament and eliminating the sac, the deep ring is abolished with a few permanent sutures

Bassini-Shouldice Hernioplasty

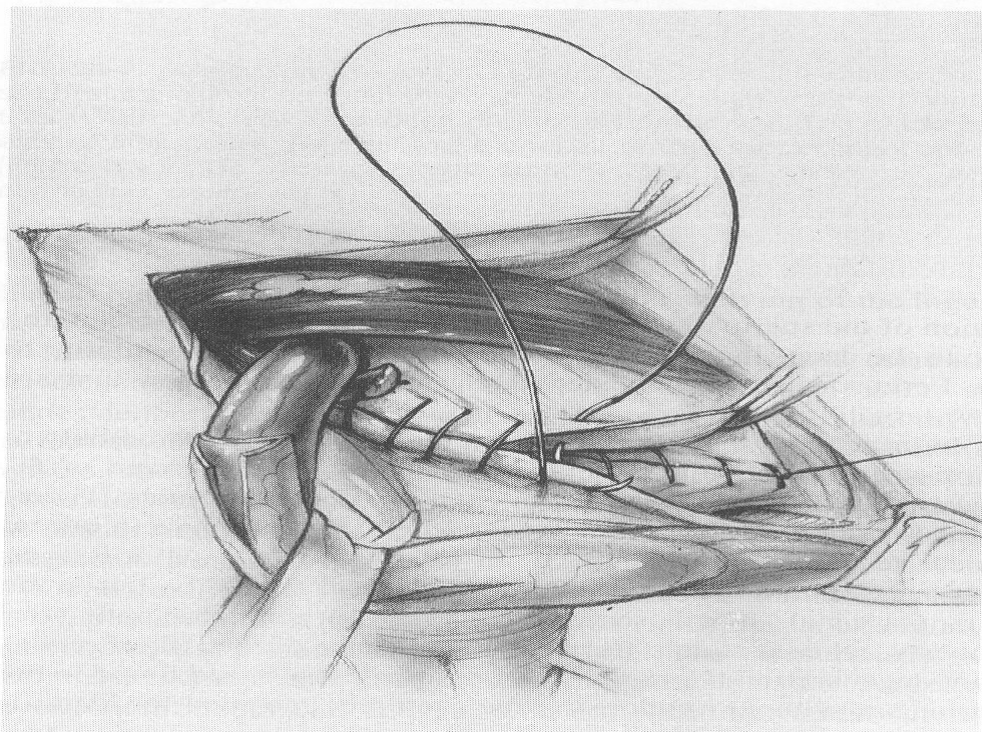
- Is indicated in all indirect hernia repair
- It consist of high ligation of the sac and approximation of the conjoined tendon and the internal oblique muscle to the shelving of the inguinal ligament with interrupted sutures or by precise imbrication with continuous sutures (shouldice)
- Does not repair the femoral canal
- Repair is none anatomic because the transversalis aponeurosis is sutured to the inguinal ligament



■ Shouldice



A

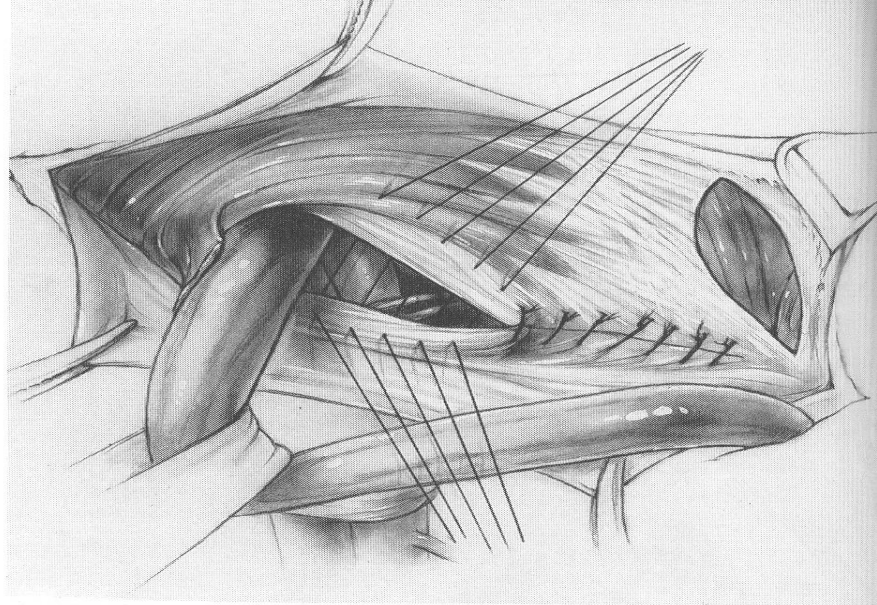


McVay Repair

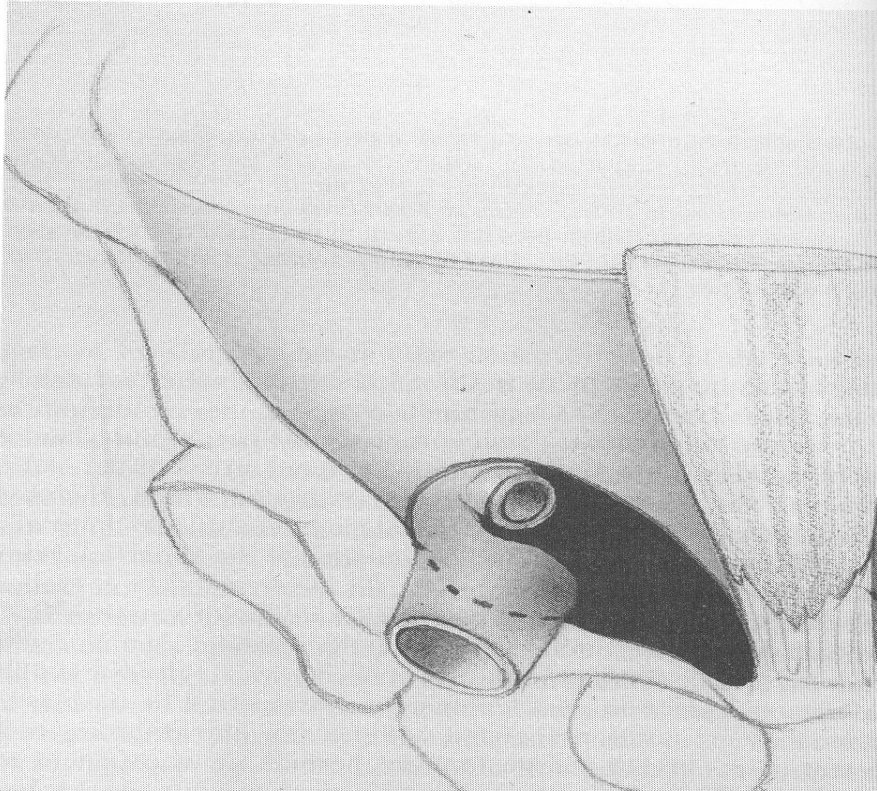
- Called Cooper ligament hernioplasty
- Repair the deep ring Hesselbush's triangle and the femoral canal
- Indicated for the three common types of hernia
- Require the excision of the medial portion of the iliopubic tract

McVay

- Excess tension is always present
- A relaxing incision is mandatory

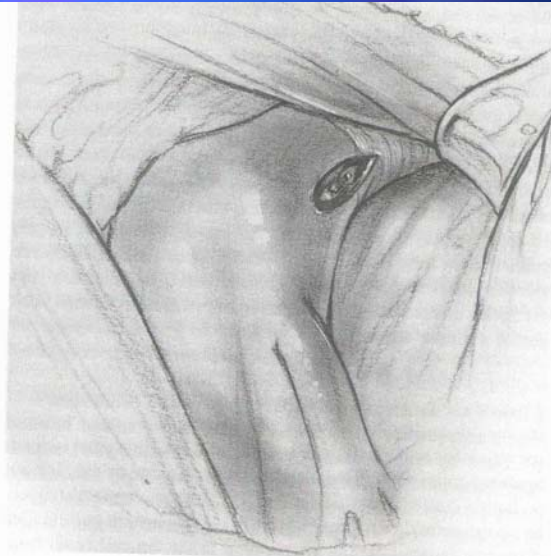


A

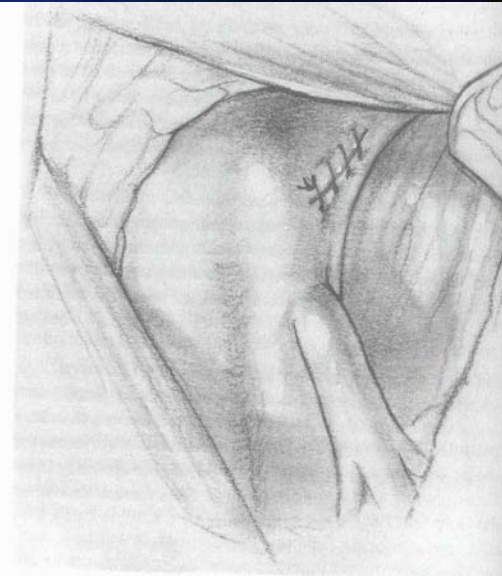

Femoral repair

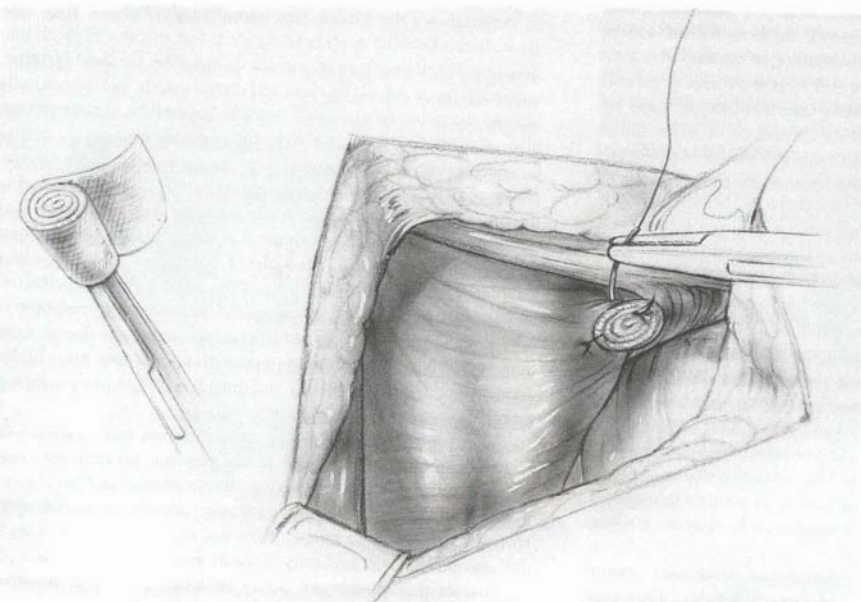
- In women repaired from below the inguinal ligament
- In men or when large hernia exist the use McVay cooper ligament repair or with a prosthesis



A



B



C

C- Closure of the inguinal canal

- The aponeurosis of the external oblique is reapproximated
- The distal stump of a divided cremaster muscle should be attached to the superficial ring to hitch up the testicle

Prosthetic material for herniolasty

Hernioplasty

- None is perfect
- Marlex, Terlex, Prolene mesh are porous knitted monofilament
- Mersilene is an open-knitted mesh composed of uncoated braided fibers of polyester Dacron
- Gore-Tex (PTFE or Teflon) is nonporous, smooth and supple through which no fluid can flow
- Gore-Tex does not incite fibroplasia or inflammation
- Polyester and polypropylene should never contact the viscera

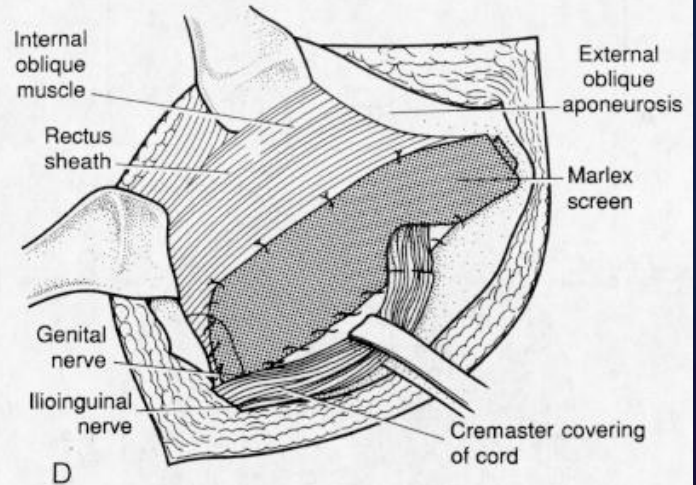
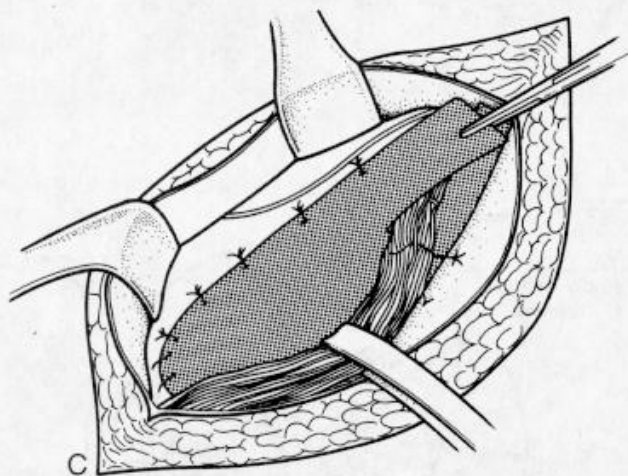
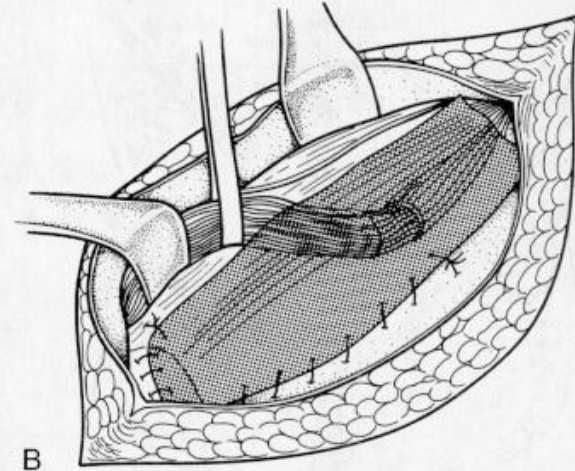
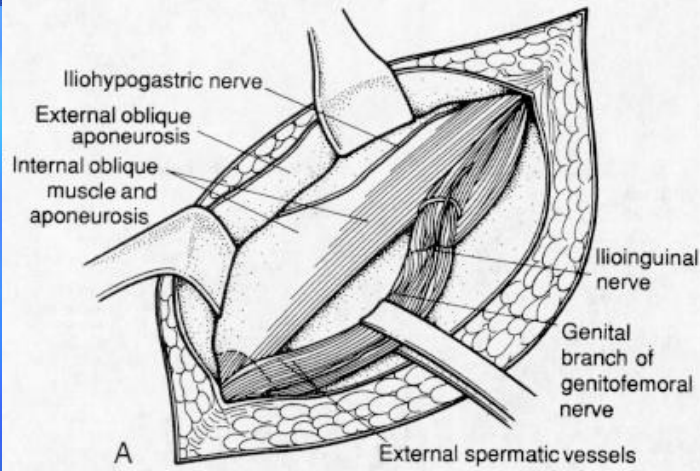
Infection of the prosthesis

- Monofilament filament tolerate infection
- They get integrated rather than infected
- Gore-Tex is intolerant of early infection because of the slow integration
- Complete integration of the monofilament can be expected in 3 to 4 weeks
- When delayed infection exist excise only the exposed part

Tension free Hernioplasty (Lichtenstein)

- Known as Giant prosthetic reinforcement of the visceral sac GPRSV
- The mesh is sutured circumferentially to the internal oblique, the rectus sheath and the shelving edge of the inguinal ligament
- The ilioinguinal nerve and the genitofemoral nerve is allowed to pass with the cord through the newly fashioned deep ring in the prosthesis
- May or may not be sutured (Gilbert's suturless tech)
- Contraindicated when hernia resulting from a connective tissue disease
- Not needed in women with indirect hernia

Lichtenstein



Posterior prosthetic hernioplasty

- Properitoneal or Stoppa procedure
- Functionally replace the transversalis fascia
- The prosthesis adhere to the peritoneum and render it inextensible so it cannot protrude (Mersilene is preferable)
- Repair of the wall defect is unnecessary
- Can be performed unilaterally or bilaterally
- Use Transverse or ant groin incision for unilateral approach
- Use Pfannensteil incision for bilateral approach

Laparoscopic Repair

- Include:
 - Transabdominal preperitoneal (TAPP) repair (uses intraperitoneal trocars and the creation of a peritoneal flap over the posterior inguinal area)
 - Totally extraperitoneal approach (TEPA). (access to the preperitoneal space without entering the peritoneal cavity).
- Repair is similar in both these techniques.
- Medial to the inferior epigastric vessels, the mesh is secured to the Cooper ligament, the lacunar ligament, the posterior rectus musculature, and the transversus abdominis aponeurotic arch.
- Laterally, the mesh is attached to the lateral extension of the transversus aponeurotic arch and the superior edge of the iliopubic tract.

Laparoscopic Repair

- Staples should not be placed below the lateral iliopubic tract because of potential injury to the genitofemoral nerve and the lateral femoral cutaneous nerve in this region.
- Stapling is also avoided in the triangular area inferior to the internal inguinal ring, called the *triangle of doom*.
- The triangle is bordered by the ductus deferens medially and the spermatic vessels laterally in the male where the external iliac artery and vein and the femoral nerve are located.
- The obturator artery is located medial to the triangle of doom but should also be avoided when securing the mesh to the Cooper ligament

TAPP

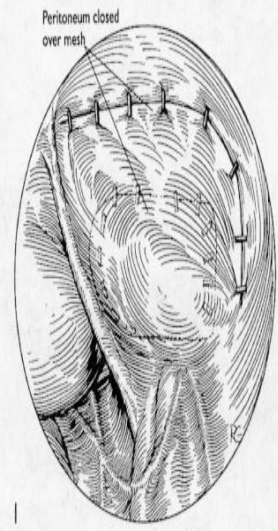
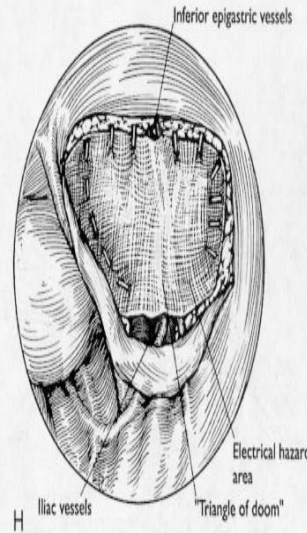
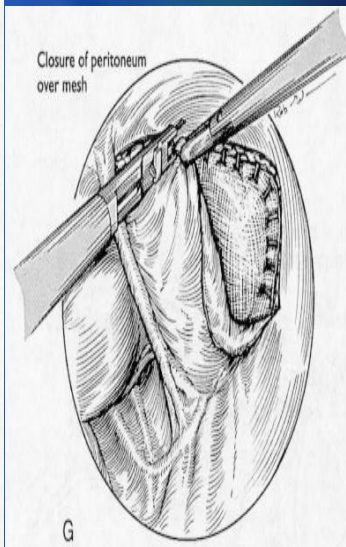
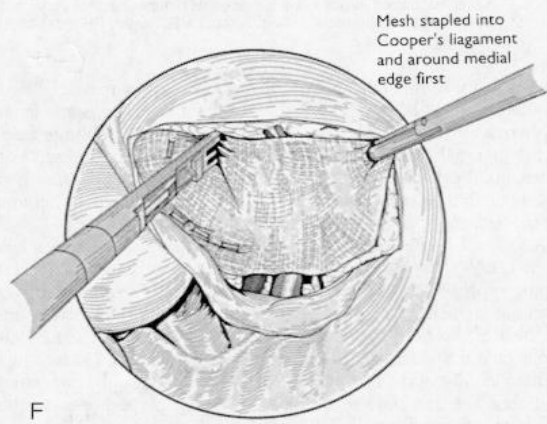
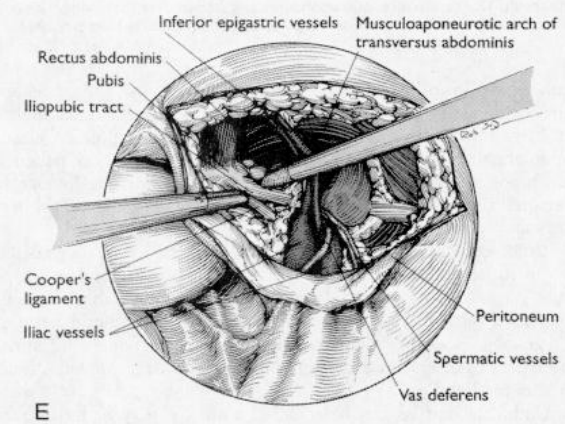
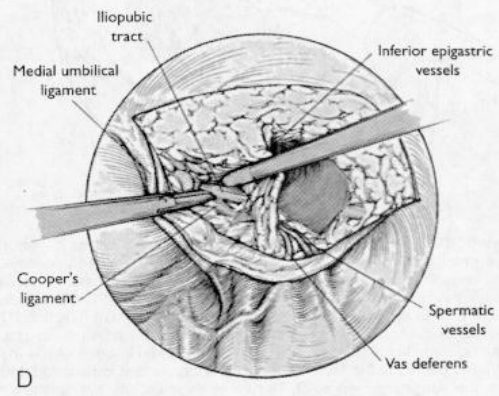
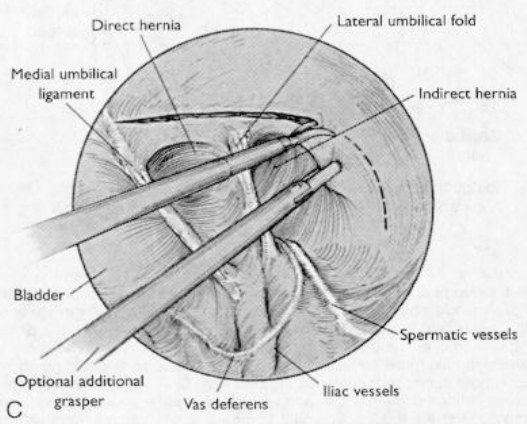
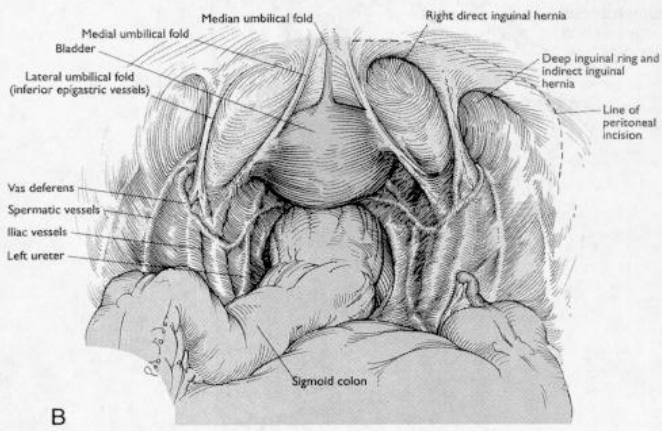
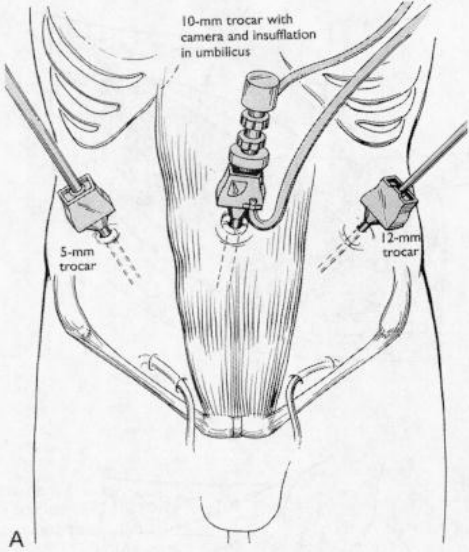


Figure 40-7 Continued G, The mesh is stapled to Cooper ligament, the posterior rectus abdominis, the transversus abdominis aponeurotic arch, and the lateral iliopubic tract. Staples are avoided in the region of the inferior epigastric vessels, the "triangle of doom," and below the lateral iliopubic tract. H, The peritoneum is closed over the mesh. I, A completed repair is demonstrated. (A, B, E, G, H, I, From Shadduck PP, Schwartz LB, Eubanks WS: Laparoscopic inguinal herniorrhaphy. In Pappas TN, Schwartz LB, Eubanks WS [eds]: Atlas of Laparoscopic Surgery. Philadelphia, Current Medicine, 1996. Copyright © 1996 by Current Medicine. Reproduced by permission of the publisher.) C, D, F, From Akhter SA, Eubanks S: Laparoscopic inguinal herniorrhaphy. In Pappas TN, Chekan EG, Eubanks S [eds]: Atlas of Laparoscopic Surgery, 2nd ed. Philadelphia, Current Medicine, 1999, pp. 3.1-3.14. Copyright © 1999 by Current Medicine. Reproduced by permission of the publisher.)

TEPA

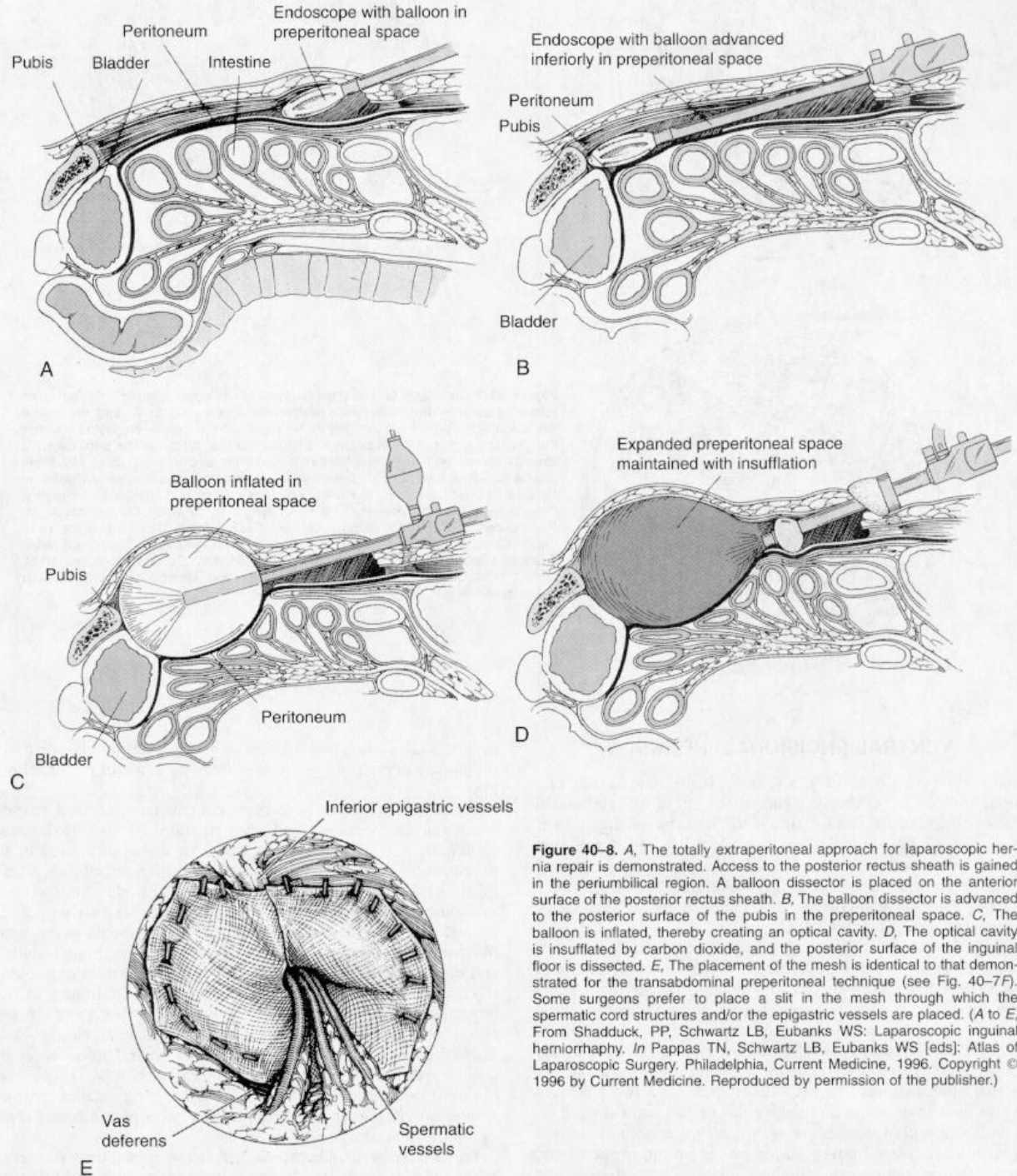


Figure 40-8. A, The totally extraperitoneal approach for laparoscopic hernia repair is demonstrated. Access to the posterior rectus sheath is gained in the periumbilical region. A balloon dissector is placed on the anterior surface of the posterior rectus sheath. B, The balloon dissector is advanced to the posterior surface of the pubis in the preperitoneal space. C, The balloon is inflated, thereby creating an optical cavity. D, The optical cavity is insufflated by carbon dioxide, and the posterior surface of the inguinal floor is dissected. E, The placement of the mesh is identical to that demonstrated for the transabdominal preperitoneal technique (see Fig. 40-7F). Some surgeons prefer to place a slit in the mesh through which the spermatic cord structures and/or the epigastric vessels are placed. (A to E, From Shadduck, PP, Schwartz LB, Eubanks WS: Laparoscopic inguinal herniorrhaphy. In Pappas TN, Schwartz LB, Eubanks WS [eds]; Atlas of Laparoscopic Surgery. Philadelphia, Current Medicine, 1996. Copyright © 1996 by Current Medicine. Reproduced by permission of the publisher.)

Laparoscopic Repair

■ Pro:

- Excellent visualization, minimal pain, rapid return to work and normal activities, small incisions that provide improved cosmesis and decreased wound infection complications, and potential cost savings secondary to decreased work loss.
- simultaneous repair of bilateral inguinal hernias.

■ Cons:

- necessity for general anesthesia, the operative costs, the violation of the peritoneal cavity (with the TAPP repair), the necessity for advanced laparoscopic skills.

UMBILICAL HERNIAS

- The vast majority of umbilical hernias are congenital in origin
- Eight times higher in black infants than in white infants
- Umbilical hernias presenting during adulthood are considered acquired hernias.
- Incarceration and strangulation are unusual; rupture can also rarely occur.
- Repaired with a variety of techniques:
 - *Pants over vest* manner as proposed by Mayo
 - Simple transverse closure of an adult umbilical hernia
 - Occasionally, mesh reinforcement is required for adequate repair of umbilical hernias.
- Recurrence of umbilical hernias is uncommon.

VENTRAL (INCISIONAL) HERNIA

- Obesity is one of the leading causes of the development of incisional hernias
- Other factors that increase the risk of developing an incisional hernia include advanced age, malnutrition, ascites, postoperative hematoma, peritoneal dialysis, pregnancy.
- Steroids and chemotherapy have been implicated in the development of incisional hernias
- The most common causative factor in the development of incisional hernias is postoperative wound infection

INCISIONAL HERNIA Repair

- Occasionally Primary repair can be accomplished.
- More commonly requires prosthetic materials:
 - Some small incisional hernias are repaired with the placement of an onlay prosthetic mesh, which overlaps the approximated fascial edges by several centimeters.
 - More commonly, prosthetic mesh is used in place of approximating the wound edges.
- The laparoscopic repair of incisional hernias has been used with increasing frequency
- Pro: Smaller wounds have resulted in a marked reduction in infections and wound complications.
- Cons: Extensive adhesiolysis is required in some patients to perform the hernia repair laparoscopically.

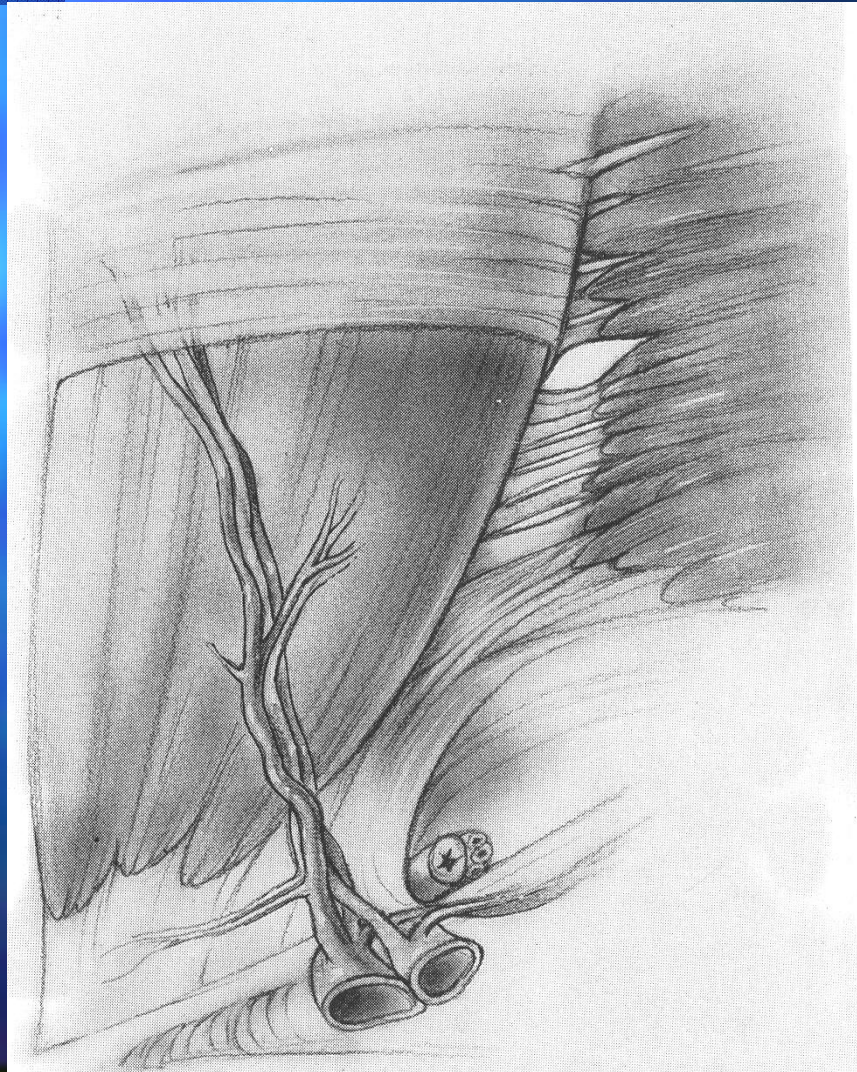
SLIDING HERNIA

- The cecum on the Right
- The sigmoid on the Left
- Ind IH are the most common types
- The hernia sac should be opened on the anteromedial border because the visceral component most commonly constitutes the posterolateral wall of the hernia sac.
- The key to successful repair of a sliding hernia is the recognition of the visceral component and the safe return of the viscera to the abdominal cavity, with a careful reconstruction of the inguinal canal.

UNUSUAL HERNIAS

- **Epigastric Hernia:**
 - More commonly above the umbilicus than below.
 - Usually small and can be difficult to diagnose in obese patients.
 - Painful, pulling sensation at the midline on reclining.
 - Repaired with simple suture closure. MAY BE MULTIPLE
- **Richter's Hernia:**
 - The antimesenteric border of the intestine must protrude into the hernia sac
 - The most common location is at the site of a femoral hernia.
 - Critical to the repair of Richter's hernia is an adequate evaluation of the intestine for viability.
- **Littre's Hernia:**
 - Meckel diverticulum as the sole component of the hernia sac
 - extremely difficult to diagnose due to the frequent lack of obstructive symptoms.
- **Spigelian Hernia:**
 - A hernia through the fascia along the lateral edge of the rectus muscle at the space between the semilunar line and the lateral edge of the rectus muscle
 - Usually successfully repaired by approximation with interrupted sutures

Spigelian Hernia



UNUSUAL HERNIAS

■ Obturator Hernia

- Weakening of the obturator membrane can lead to intestinal incarceration
- The obturator canal, which is 2 to 3 cm long, may contain a fat pad, which is considered by many surgeons to be pathologic.
- May present with evidence of compression of the obturator nerve
- Surgical repair through various approaches:
 - abdominal approach, open or laparoscopic
 - The retropubic (preperitoneal) approach is preferred by many surgeons when there are no signs of obstruction or intestinal involvement.
 - The obturator, inguinal, and combination approaches have been described.
 - The dilated obturator foramen is repaired with interrupted sutures

UNUSUAL HERNIAS

■ Lumbar (Dorsal) Hernia:

- Grynfeltt's hernia @ superior lumbar triangle
- Petit's hernia @ inferior lumbar triangle.
- Diffuse lumbar hernias are most often iatrogenic (kidney operations)
- Overlapping and imbricating suture / mesh reinforcement repairs

■ Sciatic Hernia:

- Extremely unusual hernias, difficult to diagnose, and the patient may be symptom free until intestinal obstruction occurs.
- Or a mass in the gluteal or infragluteal area + discomfort on standing.
- Sciatic nerve pain is rarely caused by pressure from a sciatic hernia.
- Repaired transabdominally or through a transgluteal approach.

■ Perineal Hernia:

- Very uncommon, may occur after abdominoperineal resection.
- A myocutaneous flap or mesh reinforcement is frequently required